

Efficacy of Temozolomide Treatment in Patients with High-grade Glioma

SHINYA OSHIRO, HITOSHI TSUGU, FUMINARI KOMATSU, TADAHIRO OHMURA, MIKA OHTA, SEISABUROU SAKAMOTO, TAKEO FUKUSHIMA and TOORU INOUE

Department of Neurosurgery, Faculty of Medicine, Fukuoka University, Fukuoka, Japan

Abstract. *Background:* Numerous studies have reported the clinical efficacy of temozolomide (TMZ) treatment for high-grade glioma, but information on Japanese populations has been limited. This study assessed the safety and early outcomes of TMZ treatment, with or without combination therapy. *Patients and Methods:* The subjects comprised ten patients with high-grade glioma [glioblastoma multiforme (GBM), n=3, gliosarcoma (GS), n=1, anaplastic oligodendroglioma (AO), n=3, anaplastic mixed oligoastrocytoma (AOA), n=1, and anaplastic ependymoma (AE), n=2]. All the patients were initially treated with conventional radiotherapy following surgical resection with or without adjuvant chemotherapy. As second- or third-line chemotherapy, patients received TMZ for recurrence or tumor progression. As combination therapy, the local administration of tumor necrosis factor- α and the addition of carboplatin and etoposide were included for three patients during the course of oral TMZ treatment. *Results:* Partial response (PR) to TMZ therapy was achieved by four out of the ten patients (objective response rate, 40%), while three patients displayed stable disease (SD) and three showed disease progression (PD). One of the patients receiving combination therapy has continued to show shrinkage of the relapsed tumor. Despite prior radio- and chemotherapy, most patients experienced only grade 1-2 hematotoxicity that was well-controlled by conservative therapy. *Conclusion:* TMZ chemotherapy is effective for the treatment of high-grade glioma in some patients without serious toxicity. Assessing the true efficacy of TMZ will require a larger study with comparison of long-term outcomes between other agents or combined therapeutic modalities.

Correspondence to: Shinya Oshiro, MD, Department of Neurosurgery, Faculty of Medicine, Fukuoka University, 45-1, 7-chome, Nanakuma, Jonan-ku, Fukuoka 814-0180, Japan. Tel: +81 92 801 1011, Fax: +81 92 865 9901, e-mail: s-oshiro@fukuoka-u.ac.jp

Key Words: Chemotherapy, high-grade glioma, temozolomide, tumor necrosis factor- α .

High-grade gliomas, among the most common primary brain tumors, are very aggressive tumors with poor prognosis despite a multi-modal treatment approach including extensive surgery, radiotherapy and nitrosourea-based chemotherapy (1, 2). Recurrence of high-grade glioma is associated with significant morbidity and limited survival. The majority of patients have already received multimodal therapy including surgery, radiotherapy and chemotherapy at initial diagnosis. Generally, conventional radiotherapy cannot be added when relapse occurs, and the therapeutic options are thus limited to further resection or adjuvant chemotherapy. Such adjuvant chemotherapy has been considered to have modest efficacy in a recurrent setting (3).

Temozolomide (TMZ) is an alkylating agent with excellent oral bioavailability, good penetration across the blood-brain barrier and a low toxicity profile (4). In 2001 the presentation of Phase II data for TMZ in addition to radiotherapy as first-line adjuvant therapy against glioblastoma multiforme (GBM) demonstrated a markedly improved 2-year survival rate compared to historical series (5). This was confirmed in a subsequent Phase III study, which reported an improvement in 2-year survival to 26% from 10% with radiotherapy alone (6). Since then, many studies have demonstrated antitumor activity of TMZ in the treatment of newly diagnosed or recurrent high-grade glioma (3, 7) and it is currently expected to improve the poor prognosis for such patients (8, 9). Furthermore, the oral formulation of TMZ is likely to be more acceptable to these patients, compared to systemic intravenous administration. Recent reports have focused on the development of strategies to optimize the clinical efficacy of TMZ using different dosing schedules and combination with other antineoplastic agents (10, 11). In Japanese populations, however, limited information has been available regarding TMZ treatment for high-grade glioma, including GBM (12).

The present study sought to elucidate the safety and feasibility of TMZ treatment and examined the early outcome data for patients with high-grade glioma who had previously received conventional radiotherapy with or without other combination therapy.

Patients and Methods

Patient selection. The subjects comprised ten patients (5 men, 5 women) with high-grade glioma and a median age of 49 years (range, 33-72 years). The histological diagnoses included GBM (grade IV; n=3), gliosarcoma (GS, grade IV; n=1), anaplastic oligodendroglioma (AO, grade III; n=3), anaplastic mixed oligastrocytoma (AOA, grade III; n=1) and anaplastic ependymoma (AE, grade III; n=2), according to the revised WHO criteria (13). Two of the patients presented with newly diagnosed glioma, while the others displayed recurrent disease. All the patients were supervised by the Department of Neurosurgery at Fukuoka University Hospital between September 2006 and December 2007. All the patients gave written informed consent. The protocol was reviewed and approved by the local ethics committees.

Selection criteria. Eligible patients were required to show adequate liver, bone marrow, renal and cardiovascular function, granulocyte count >1500/ml, platelet count >10×10⁴/ml, hemoglobin >10 g/ml, serum glutamic-pyruvic transaminase and alkaline phosphatase <2 times normal, bilirubin <1.5 mg% and blood urea nitrogen or creatinine <1.5 times normal prior to starting therapy.

Initial surgery. All the patients underwent extensive resection, depending on tumor location. The extent of resection was evaluated based on operative reports and postoperative magnetic resonance imaging (MRI) as grossly total, subtotal (>95%) or partial resection (5-95%).

Initial adjuvant therapy. After the surgical resection of the tumor, all the patients underwent a course of radiotherapy (standard dose ranging from 54-60 Gy at 1.5 Gy/day 5 times/week). As initial induction chemotherapy, ranimustine (MCNU) was used against anaplastic astroglial tumors or a procarbazine, MCNU, vincristine (PMV) regimen was selected against anaplastic oligodendroglial tumors for first-line chemotherapy. Substantially, MCNU was administered intravenously at 100 mg/m² on day 1, *i.e.* at onset of radiotherapy and was then administered every 8 weeks until tumor progression. With the PMV regimen, MCNU was initially administered intravenously at 100 mg/m² on day 1 followed by 1.4 mg/m² vincristine intravenously on days 8 and 29. Between days 8 and 21, procarbazine was administered orally at 60 mg/m². This PMV regimen was given in 6-week cycles until tumor progression was evident or for a total of 6 cycles. For local immunotherapy, tumor necrosis factor (TNF)-alpha was administered into the postoperative tumor cavity through an Ommaya reservoir at a concentration of 1×10⁴ U/body. This local TNF-alpha treatment continued at intervals of 1 or 2 weeks until tumor progression. Institutional board approval was obtained for treatment with TNF-alpha (14).

Follow-up management. All the patients were monitored for tumor recurrence or progression during the initial or maintenance therapy. When the patients showed any evidence of recurrence or progression during this period, they underwent debulking surgery if possible. When a second resection was impossible, a carboplatin and etoposide (CE) regimen was started as second-line chemotherapy. Carboplatin was administered intravenously at a dose of 400 mg/m² on day 1 and etoposide was also infused intravenously at a dose of 100 mg/m² for 3 days (day 1 to day 3). This treatment was repeated every 8 weeks until further tumor progression was evident or for a total of 5 cycles.

TMZ management. From September 2006, the TMZ treatment regimen was introduced for recurrence or tumor progression as second- or third-line chemotherapy in the ten patients. In nine patients, the TMZ was administered orally at 150 mg/m²/day on day 1-5 for the first cycle. The dose was increased to 200 mg/m²/day beginning with the second cycle, as long as no hematological toxicity was encountered. Treatment cycles were repeated every 28 days (standard 5-day schedule) until development of neurological or radiological deterioration. In one patient with newly diagnosed AO (Case 6), concomitant TMZ chemotherapy was administered at a dose of 75 mg/m²/day, 7 days/week from the first day of radiotherapy until the last day of radiotherapy. After a 4-week break, patients were then to receive up to the standard 5-day schedule every 28 days. A full blood examination was performed twice prior to each new cycle.

Clinical data collection and statistical analyses. All the medical records were reviewed and entered into a database. Common toxicities were defined using the Common Terminology Criteria for Adverse Events (CTCAE) scale. The parameters that were monitored to determine response to therapy included neurological status and tumor size as measured on gadolinium-enhanced MRI before and after each treatment or at 3-month intervals. The tumor size was estimated as the volume of abnormally enhanced lesion on MRI. Response was classified into one of 4 categories; complete response (CR), complete disappearance of tumor for a period of ≥4 weeks; partial response (PR), reduction of ≥50% in tumor size for ≥4 weeks; stable disease (SD), either a decrease of <50% or an increase of <25% in tumor size for ≥4 weeks and progressive disease (PD), an increase of ≥25% in tumor size or appearance of tumor in a previously uninvolved area.

Results

Patient characteristics. Table I summarizes the patient characteristics. Grossly total resection was achieved in three patients and subtotal resection was performed in five patients at initial surgery. As first-line chemotherapy, MCNU was administered in four patients and the PMV regimen was administered in three patients after initial surgery. In one patient with AE (Case 9), only adjuvant radiotherapy was performed without any maintenance therapy. Systemic administration of interferon (IFN)-beta was performed in one patient (Case 3) and local TNF-alpha immunotherapy was used in two patients (Cases 7, 8) as maintenance therapy. Since the first relapse was observed in three patients (Cases 2, 4 and 5), the CE regimen was started as second-line chemotherapy after the second debulking surgery.

Efficacy and short-term outcome of TMZ treatment. The TMZ treatment regimen was introduced for the ten patients and Table II summarizes the early outcome data. The median number of TMZ treatment cycles was 7.0 (range, 1-17) and the median follow-up period after initial treatment with the TMZ regimen was 8.6 months (range, 4-15 months). Out of the ten patients, six discontinued TMZ treatment because of failure to respond or side-effects with drug-induced allergy at the time of data collection. The other four patients continued

Table I. *Clinical profiles and patient characteristics.*

Case	Age/ gender	New/ recurrent	Diagnosis* (WHO grade)	First-Surgery	RT	First-line chemotherapy	Maintenance therapy	Second-line chemotherapy
1	51/M	New	GBM (4)	Subtotal	+	MCNU (1)	-	-
2	51/M	Recurrent	GS (4)	Subtotal	+	MCNU (2)	-	CE (1)
3	65/F	Recurrent	GBM (4)	Subtotal	+	MCNU (1)	IFN	-
4	45/M	Recurrent	AO (3)	Partial	+	PMV (6)	-	CE (3)
5	45/F	Recurrent	AO (3)	Total	+	PMV (1)	-	CE (5)
6	72/F	New	AO (3)	Subtotal	+	-	-	-
7	36/M	Recurrent	AA (3)→GBM (4)	Total	+	MCNU (8)	Local-TNF(18M)	-
8	49/F	Recurrent	AE (3)	Total	+	-	Local-TNF(70M)	-
9	43/M	Recurrent	AE (3)	Subtotal	+	-	-	-
10	33/F	Recurrent	AOA (3)	Partial	+	PMV (4)	-	-

RT, radiotherapy; MCNU, ranimustine; PMV, procarbazine + MCNU + vincristine; CE, carboplatin + etoposide; IFN, interferon-beta; Local-TNF, local tumor necrosis factor-alpha administration. AA, anaplastic astrocytoma; AE, anaplastic ependymoma; AO, anaplastic oligodendroglioma; AOA, anaplastic mixed oligoastrocytoma; GBM, glioblastoma multiforme. 1st- or 2nd-line chemotherapy; () number of cycles. Maintenance therapy; () duration in months. Diagnosis*; malignant transformation to GBM from AA was observed in Case 7 on second surgery.

Table II. *Clinical profiles and outcome of TMZ treatment.*

Case	Diagnosis (WHO grade)	Starting day (TMZ)	Combination therapy	Cycles (TMZ)	Response	Adverse effect (grade)	PFS (W)	Outcome
1	GBM (4)	19/9/2006	-	17~	PR	Limb edema (1)	67	Alive
2	GS (4)	26/9/2006	-	1	PD	-	9	Dead
3	GBM (4)	27/9/2006	Local-TNF (1.5M)	9	PD	-	5	Dead
4	AO (3)	29/9/2006	-	7	PR	Leukopenia (2)	28	Dead
5	AO (3)	22/1/ 2007	-	7	SD	Leukopenia (2)	12	Dead
6	AO (3)	24/4/2007	-	2	SD	Allergic reaction (2)	35	Alive
7	AA (3)→GBM (4)	26/4/2007	CE (3)	6	PD	Thrombocytopenia (1)	16	Alive
8	AE (3)	11/5/2007	Local-TNF (5M)	8~	PR	Thrombocytopenia (1)	33	Alive
9	AE (3)	28/5/2007	-	8~	PR	Leukopenia (1)	31	Alive
10	AOA (3)	8/8/2007	-	5~	SD	Leukopenia (2)	20	Alive

Cycle, ~ under treatment with TMZ and outcome, at time of data collection. PR, partial response; PD, progressive disease; SD, stable disease. AA, anaplastic astrocytoma; AE, anaplastic ependymoma; AO, anaplastic oligodendroglioma; AOA, anaplastic mixed oligoastrocytoma; GBM, glioblastoma multiforme. PFS, progression-free survival; W, weeks. Adverse effect, Common Terminology Criteria for Adverse Events (CTCAE).

to be treated and remained alive with disease. During the course of TMZ chemotherapy, two patients with GBM (Case 3) and AE (Case 8) received combination immunotherapy with local TNF-alpha administration. One patient with GBM (Case 7) also received combination chemotherapy with the CE regimen due to aggressive growth of the tumor despite the use of TMZ. As a result, four patients achieved PR, three patients displayed SD and three patients experienced PD in response to TMZ treatment with/without combination therapy (overall objective response rate, 40%). Although the majority of patients with GBM showed a poor response, one GBM patient (Case 1) has maintained significant shrinkage of the tumor lesion with progression-free survival of 67 weeks. Only three patients (Cases 2, 3 and 7) did not show any response to TMZ chemotherapy.

TMZ toxicity. TMZ treatment was relatively well tolerated. Toxicity during 63 courses of therapy was mild. CTCAE grade 2 leukopenia without any treatment occurred in three patients and grade 1 leukopenia was observed in one patient. CTCAE grade 1 thrombocytopenia was confirmed in two patients, but anemia was not seen at any stage of the study. One patient displayed pitting edema on the lower limbs with CTCAE grade 1 and one patient discontinued treatment with TMZ as a probable cause of drug-induced allergy (allergic reaction, CTCAE grade 2). No reports of infection or patients hospitalized for complications of TMZ treatment were encountered.

Representative cases. Case 1, a 51-year-old man who presented with headache and right-sided weakness underwent subtotal removal of left frontal lobe GBM in July 2006

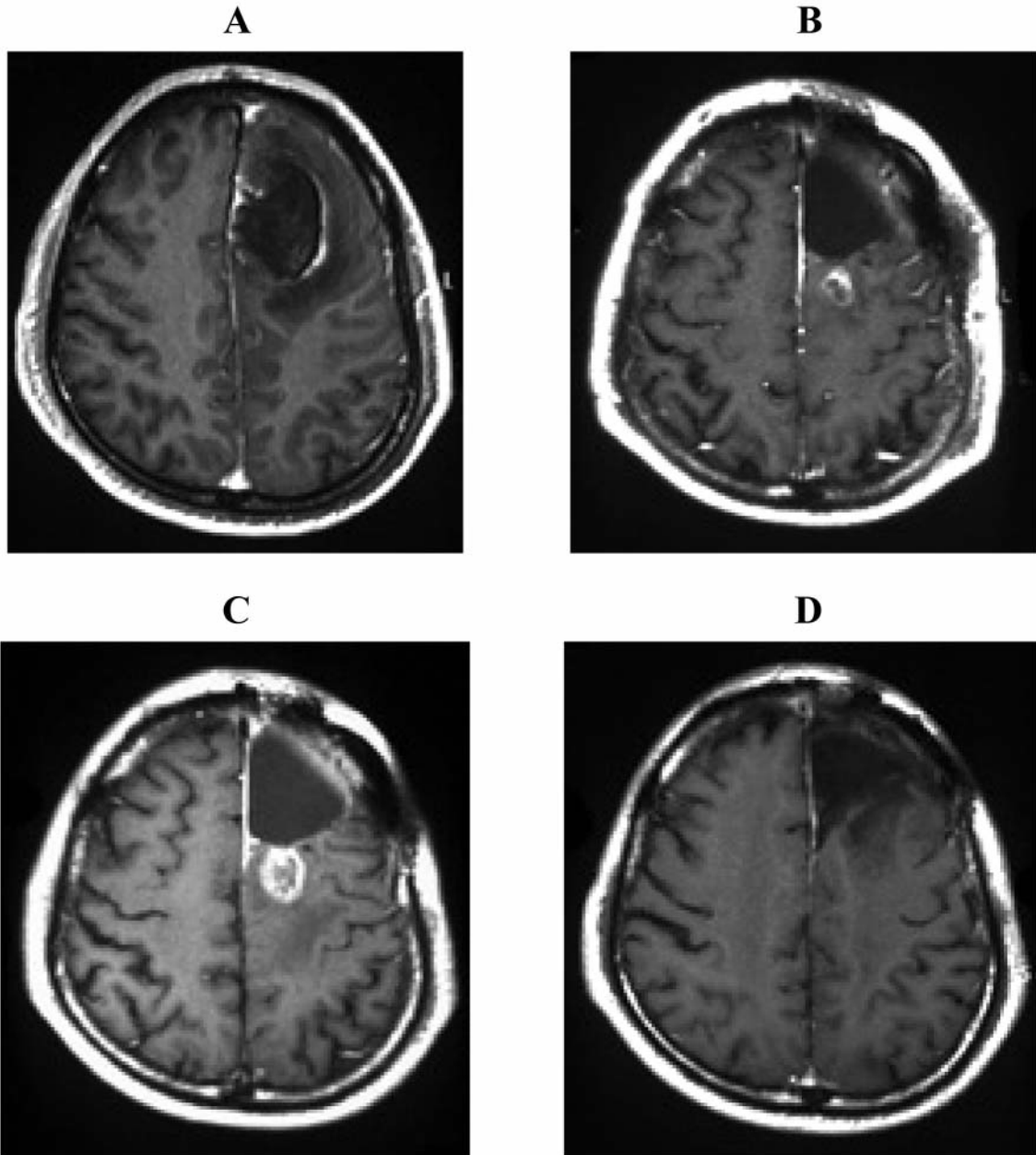


Figure 1. Case 1 with glioblastoma multiforme. Gadolinium-enhanced MRI before surgery shows a left frontal mass lesion with annular enhancement (A). Residual tumor post-radiotherapy MRI (B). Remnant tumor after finishing 3 cycles of TMZ regimen (C). Shrinkage of the lesion on serial MRI after finishing 13 TMZ cycles (D).

(Figure 1A). After surgery, multimodal therapy with conventional radiotherapy and MCNU treatment was performed as induction therapy. Since residual tumor was observed on post-radiotherapy MRI (Figure 1B), TMZ chemotherapy was started as maintenance therapy. The patient was treated with the usual 5-day protocol repeated in cycles every 28 days. The remnant tumor, however, continued to grow slowly on serial MRI after finishing 3 cycles of TMZ

treatment (Figure 1C). After 8 cycles of treatment, the tumor began to shrink and showed further shrinkage of the lesion in October 2007 (Figure 1D). During this chemotherapy, no steroid was administered and no significant side-effects exceeding CTCAE grade 2 were seen up to November 2007.

Case 4, a 45-year-old man presented with dizziness and underwent a partial resection of the left frontal lobe AO in November 2000. After the initial surgery, conventional

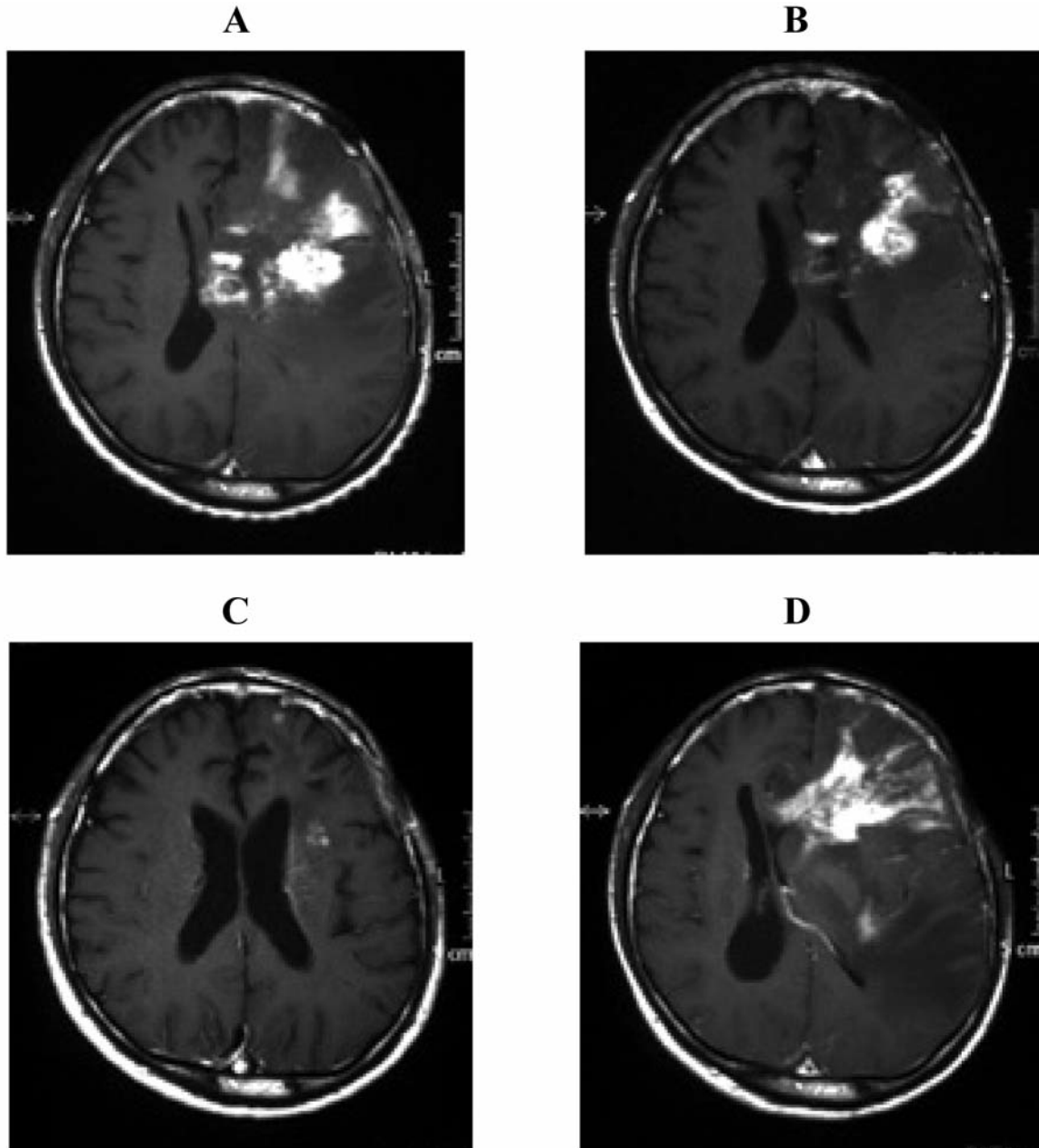


Figure 2. Case 4 with recurrent anaplastic oligodendroglioma. Gadolinium-enhanced MRI obtained at second relapse shows a left frontal mass lesion with heterogeneous enhancement (A). Just after finishing the first cycle of the TMZ regimen, MRI demonstrated shrinkage of the relapsed tumor (B). On finishing 5 cycles of treatment, most of the tumor had disappeared (C). However, repeated relapse was detected and tended to progress rapidly after discontinuation of TMZ chemotherapy (D).

radiotherapy and chemotherapy with the PMV regimen were administered against the remnant tumor. Follow-up MRI showed a decrease in tumor volume of >50%. The patient remained clinically stable for approximately 5 years without any maintenance therapy. However, regrowth of the lesion was noted on serial MRI and a second debulking surgery was undertaken. After the second surgery, the CE treatment

regimen was introduced as second-line chemotherapy. Although the tumor volume decreased transiently, follow-up MRI revealed enlargement of the residual tumor (Figure 2A). TMZ chemotherapy was then started in September 2006 as third-line chemotherapy. Interestingly, the neurological symptoms improved immediately during this first cycle of TMZ and subsequent MRI after finishing the cycle showed

significant shrinkage of the relapsed tumor (Figure 2B). The neurological symptoms showed further concomitant improvement. After finishing 5 cycles, the majority of the residual tumor had disappeared (Figure 2C). However, repeated relapse was detected even after successful treatment with TMZ. The relapsed lesion tended to progress rapidly after discontinuation of TMZ chemotherapy (Figure 2D) and the patient eventually died, 8 months after starting treatment with TMZ.

Discussion

In the current study, of with TMZ treatment as second- or third-line chemotherapy, four of the patients achieved PR (objective response rate, 40%). Three patients displayed SD in response to treatment. The notion that SD constitutes 'a response' is not generally accepted in the field of oncology. However, achieving a stable state in the context of high-grade glioma has been shown to have significant prognostic effects (3). The present results thus implied significant activity of the drug, with a 70% overall response rate (CR, PR or SD). The response rate to the standard 5-day protocol for TMZ treatment is reportedly 7-30% in patients with GBM or anaplastic astrocytoma (AA) (15-17). In some series of recurrent high-grade glioma, median progression-free survival (PFS) is thought to be only 2.1 months for GBM and 5.4 months for AA (16, 17). With the small numbers of patients treated in the present series, no apparent difference was noted in response to the TMZ treatment compared to other reported series.

Myelosuppression is the most serious adverse effect of TMZ and is dose-limiting. However, this effect does not appear to be cumulative and is relatively easily treated (7). In the present series, TMZ treatment was extremely well tolerated with few significant side-effects. Despite prior radiotherapy and some chemotherapy, most of the patients experienced only grade 1-2 hematotoxicity that could be well controlled with conservative therapy. Only one patient had to discontinue TMZ treatment due to allergic reaction with CTCAE grade 2. No infection or toxic side-effects were reported and no patients were hospitalized for complications of the TMZ regimen.

Although TMZ is currently one of the most effective chemotherapeutic agents for treatment of high-grade glioma, not all patients benefit from the drug. Recently, several reports focusing on different dosing schedules or combination therapies together with TMZ have described such situations (10, 11). The antitumor activity of TMZ reportedly lasts only a few months, with drug resistance developing thereafter in most cases (15, 17), although TMZ demonstrates promising activity against high-grade glioma in some patients. Resistance to TMZ is considered to be mediated, at least to some extent, by a DNA repair enzyme,

O⁶-methylguanine DNA methyltransferase (MGMT), which is induced in tumor tissues (18). IFN-beta is considered to suppress MGMT function, resulting in some enhancement of TMZ activity (19, 20). Conversely, TNF-alpha, as used in our series, is thought to act as a direct tumor-suppressor or immunomodulator with similar function to IFN-beta (21). Combination therapy with intratumoral TNF-alpha administration was performed in two patients during the oral TMZ treatment and one patient with AE has been continuing to show shrinkage of the relapsed tumor on serial MRI. Although the tumor may develop some resistance to TNF-alpha treatment during the course of this therapy, additional stimulation with oral TMZ may cause sensitivity reactions against subsequent TNF-alpha treatment.

In conclusion, TMZ is a new and reasonably well-tolerated bioactive oral chemotherapeutic agent for treating high-grade glioma, including GBM. A place has been established for TMZ in the standard care for the treatment of recurrent or newly diagnosed lesions. The present series of ten patients with high-grade glioma substantiates the potential efficacy of TMZ chemotherapy with or without other combination therapies. Assessing the true efficacy of TMZ will require a larger study with comparison with other agents and combined therapeutic modalities.

References

- 1 Burger PC, Vogel FS, Green SB and Strike TA: Glioblastoma multiforme and anaplastic astrocytoma. *Cancer* 56: 1106-1111, 1985.
- 2 Stupp R, Hegi ME, van den Bent MJ, Mason WP, Weller M, Mirimanoff RO and Cairncross JG: Changing paradigms – an update on the multidisciplinary management of malignant glioma. *Oncologist* 11: 165-180, 2006.
- 3 Yang S-H, Kim M-K, Lee T-K, Lee K-S, Jeun S-S, Park C-K, Kang J-K, Kim M-C and Hong Y-K: Temozolomide chemotherapy in patients with recurrent malignant gliomas. *J Korean Med Sci* 21: 739-744, 2006.
- 4 Brada M, Judson I, Beale P, Moore S, Reidenberg P, Statkevich P, Dugan M, Batra V and Cutler D: Phase I dose-escalation and pharmacokinetic study of temozolomide (SCH 52365) for refractory or relapsing malignancies. *Br J Cancer* 81: 1022-1030, 1999.
- 5 Stupp R, Dietrich PY, Ostermann Kraljevic S, Pica A, Maillard I, Maeder P, Meuli R, Janzer R, Pizzolato G, Miralbell R, Porchet F, Regli L, de Tribolet N, Mirimanoff RO and Leyvraz S: Promising survival for patients with newly diagnosed glioblastoma multiforme treated with concomitant radiation plus temozolomide followed by adjuvant temozolomide. *J Clin Oncol* 20: 1375-1382, 2002.
- 6 Stupp R, Mason WP, van den Bent MJ, Weller M, Fisher B, Taphoorn MJ, Belanger K, Brandes AA, Marosi C, Bogdahn U, Curschmann J, Eisenhauer E and Mirimanoff RO: Radiotherapy plus concomitant and adjuvant temozolomide for glioblastoma. *N Engl J Med* 352: 987-996, 2005.
- 7 DeAngelis LM: Chemotherapy for brain tumors. A new beginning. *N Engl J Med* 352: 1036-1038, 2005.

- 8 Back MF, Ang ELL, Ng WH, See S-J, Lim CCT, Chan SP and Yeo T-T: Improved median survival for glioblastoma multiforme following introduction of adjuvant temozolomide chemotherapy. *Ann Acad Med Singapore* 36: 338-342, 2007.
- 9 Hau P, Koch D, Hundsberger T, Marg E, Bauer B, Rudolph R, Rauch M, Brenner A, Rieckmann P, Schuth J, Jauch T, Koch H and Bogdahn U: Safety and feasibility of long-term temozolomide treatment in patients with high-grade glioma. *Neurology* 68: 688-690, 2007.
- 10 Fujimaki T, Ishii H, Matsuno A, Arai H and Nakagomi T: Effectiveness of interferon-beta and temozolomide combination therapy against temozolomide-refractory recurrent anaplastic astrocytoma. *World J Surg Oncol* 5: 89-93, 2007.
- 11 Wick A, Felsberg J, Steinbach JP, Herrlinger U, Platten M, Blaschke B, Meyermann R, Reifenberger G, Weller M and Wick W: Efficacy and tolerability of temozolomide in an alternating weekly regimen in patients with recurrent glioma. *J Clin Oncol* 25: 3357-3361, 2007.
- 12 Kobayashi H, Sawamura Y, Ishii N, Murata J and Iwasaki Y: Temozolomide in the treatment of recurrent malignant glioma. *No Shinkei Geka* 34: 1241-1247, 2006 (in Japanese).
- 13 Kleihues P, Burger PC, Scheithauer BW (eds.): *Histological Typing of Tumors of the Central Nervous System*. 2nd edition. Berlin, Springer-Verlag, pp. 11-20, 1993.
- 14 Oshiro S, Tsugu H, Komatsu F, Ohnishi H, Ueno Y, Sakamoto S, Fukushima T and Soma G-I: Evaluation of intratumoral administration of tumor necrosis factor-alpha in patients with malignant glioma. *Anticancer Res* 26: 4027-4032, 2006.
- 15 Nishikawa R, Shibui S, Maruo M, Sugiyama K, Sato S, Fujimaki T, Takahashi H, Wakabayashi T, Takahashi J, Kochi M, Nakamura H, Sawamura Y, Ikeda J, Hori T, Aoki T and Matsutani M: Efficacy and safety of monotherapy with temozolomide in patients with anaplastic astrocytoma at first relapse – a phase II clinical study. *Gan to Kagaku Ryoho* 33: 1279-1285, 2006.
- 16 Brada M, Hoog-Xuan K, Rampling R, Dietrich PY, Dirix LY, Macdonald D, Heimans JJ, Zonnenberg BA, Bravo-Marques JM, Henriksson R, Stupp R, Yue N, Bruner J, Dugan M, Rao S and Zaknoen S: Multicenter phase II trial of temozolomide in patients with glioblastoma multiforme at first relapse. *Ann Oncol* 12: 259-266, 2001.
- 17 Yung WK, Prados MD, Yaya-Tur R, Rosenfeld SS, Brada M, Friedman AH, Bruner J, Yue N, Dugan M, Zaknoen S and Levin VA: Multicenter phase II trial of temozolomide in patients with anaplastic astrocytoma or anaplastic oligoastrocytoma at first relapse. *Temodal Brain Tumor Group. J Clin Oncol* 17: 2762-2771, 1999.
- 18 Hegi ME, Diserens AC, Gorlia T, Hamou MF, de Tribolet N, Weller M, Kros JM, Hainfellner JA, Mason W, Mariani L, Bromberg JE, Hau P, Mirimqnoff RU, Cairncross JG, Janzer RC and Stupp R: MGMT gene silencing and benefit from temozolomide in glioblastoma. *N Engl J Med* 352: 997-1003, 2005.
- 19 Natsume A, Ishii D, Wakabayashi T, Tsuno T, Hatano H, Mizuno M and Yoshida J: IFN-beta down-regulates the expression of DNA repair gene MGMT and sensitizes resistant glioma cells to temozolomide. *Cancer Res* 65: 7573-7579, 2005.
- 20 Park JA, Joe YA, Kim TG and Houg YK: Potentiation of antiglioma effect with combined temozolomide and interferon-beta. *Oncol Rep* 16: 1253-1260, 2006.
- 21 Yamini B, Yu X, Pytel P, Galanopoulos N, Rawlani V, Veerapong J, Bickenbach K and Weichselbaum RR: Adenovirally delivered tumor necrosis factor-alpha improves the antiglioma efficacy of concomitant radiation and temozolomide therapy. *Clin Cancer Res* 13: 6217-6223, 2007.

Received May 28, 2008
Revised January 14, 2009
Accepted January 19, 2009